

# ON-DEMAND USE OF L-MENTHOL MAY SUBSTITUTE FOR THE ROUTINE USE OF ANTI-PERISTALTIC DRUGS IN ESOPHAGOGASTRODUODENOSCOPY

Kengo Onochi<sup>1,2)</sup>, Takuji Gotoda<sup>2,3)</sup>, Hirosato Mashima<sup>1,4)</sup>, Chika Kusano<sup>2,3)</sup> and Katsunori Iijima<sup>1)</sup>

(received 27 October 2016, accepted 19 December 2016)

<sup>1)</sup>*Department of Gastroenterology, Akita University Graduate School of Medicine*

<sup>2)</sup>*Department of Gastroenterology, Yuri Union General Hospital*

<sup>3)</sup>*Department of Gastroenterology and Hepatology, Nihon University School of Medicine*

<sup>4)</sup>*Department of Gastroenterology, Saitama Medical Center, Jichi Medical University*

## Abstract

**Background :** In Japan, anti-peristaltic drugs are routinely injected as a countermeasure to control the occurrence of spasms during esophagogastroduodenoscopy (EGD). However, few reports have so far shown these drugs to improve the quality of diagnostic EGD. We evaluated the requirement of anti-peristaltic premedication and the efficacy of the selective use of L-menthol.

**Methods :** 173 patients who underwent EGD screening were enrolled prospectively. Endoscopy was performed without the administration of any anti-peristaltic drugs. The degree of gastric peristalsis was assessed when the endoscope reached the antrum. Gastric peristalsis was classified into three grades : none, mild or severe. When gastric peristalsis was severe, 20 mL of 0.8% L-menthol was sprayed endoscopically on the gastric mucosa. Thereafter, we again assessed the grade of peristalsis and measured the time interval until peristalsis was suppressed.

**Results :** The peristaltic grade observed without the use of any anti-peristaltic drugs was none or mild in 88.5% of the patients. After spraying L-menthol, the proportion of subjects with severe peristalsis was 0.0% and EGD screening was performed satisfactorily.

**Conclusions :** The routine use of premedication with anti-peristaltic drugs during EGD screening may not be necessary. When severe peristalsis interferes with precise observation, the use of L-menthol is easy and sufficient.

**Key words :** Screening, L-Menthol, Gastric Motility, Peristalsis, Gastrointestinal Endoscopy

## Introduction

Esophagogastroduodenoscopy (EGD) is widely used to diagnose and treat upper gastrointestinal (GI) diseases

---

Corresponding author : Kengo Onochi  
 Department of Gastroenterology, Akita University Graduate School of Medicine, 1-1-1 Hondo, Akita 010-8543, Japan  
 Tel : 81-18-884-6104  
 Fax : 81-18-836-2611  
 E-mail : onochi.k@gmail.com

es. It is now possible to detect small lesions of gastric tumors on EGD and resect them endoscopically. Gastric peristalsis sometimes interferes with precise observation. In Japan, hyoscine-N-butylbomide or glucagon is usually injected as a countermeasure to control spasm during EGD. However, it has been reported that these agents are associated with complications<sup>1)</sup>. Hyoscine-N-butylbomide may induce cardiovascular events and/or anaphylactic shock<sup>2)</sup> and may also affect the ocular, urinary and salivary systems<sup>3)</sup>. Glucagon can cause de-

layed hypoglycemia<sup>4,5</sup>. Moreover, there are few reports that show these anti-peristaltic drugs to improve the quality of diagnostic EGD.

In this study, we evaluated the frequency of inadequate observation during EGD screening without the use of any anti-peristaltic drugs. We also examined whether severe peristalsis could be controlled by L-menthol and compared the medical costs of using L-menthol instead of standard anti-peristaltic drugs.

## Methods

### Patients

This study was performed at Yuri Union General Hospital, Akita, Japan in February 2011. Consecutive patients who underwent EGD screening were enrolled. The following exclusion criteria were applied :

1. previous gastrectomy, 2. upper GI bleeding requiring hemostasis, 3. severe gastric stenosis or deformation and 4. a poor endoscopic view due to the presence of excessive saburra. We obtained informed consent from all patients before their enrollment in this study. The study was conducted in accordance with the Declaration of Helsinki.

### Study design

Seven endoscopists took part in the study. All of the endoscopists had performed more than 1000 EGD procedures. Prior to undergoing endoscopy, the patients were asked whether they had severe heart disease, prostatic hypertrophy or narrow angle glaucoma. Topical pharyngeal anesthesia was induced by spraying lidocaine. In each case, the endoscope was inserted into the patient's stomach without the use of any anti-peri-

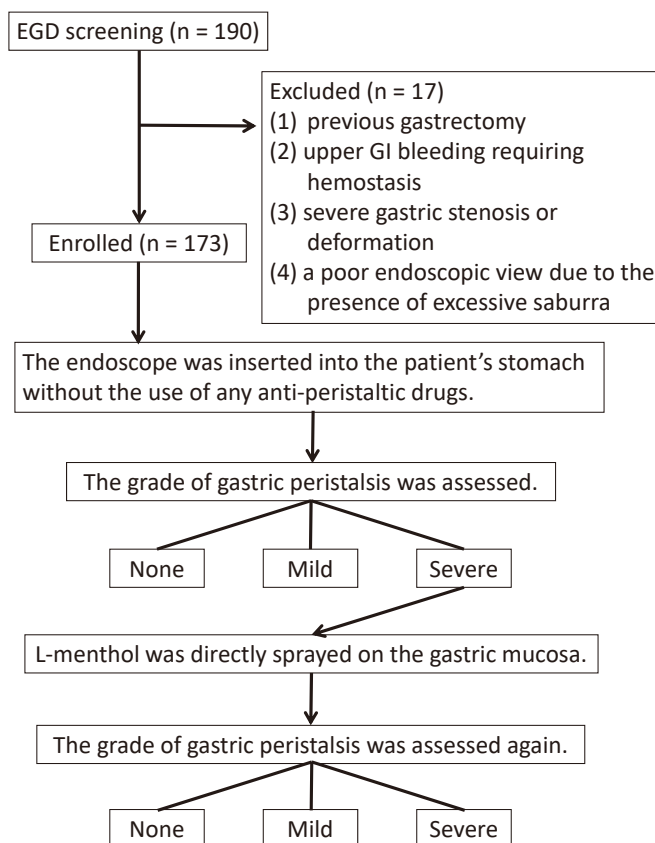


Fig. 1. Study design

staltic drugs or sedation. The grade of gastric peristalsis was assessed when the endoscope reached the antrum. When gastric peristalsis was severe, 20 mL of 0.8% L-menthol (Minclea<sup>®</sup>; a drug approved for use in antispasmodic, Nihon Pharmaceutical Co., Ltd, Tokyo, Japan) was directly sprayed on the gastric mucosa through the accessory channel of the endoscope. Thereafter, the grade of peristalsis was again assessed and the time interval from spraying L-menthol to the disappearance of peristalsis was measured (Fig. 1). Then, a precise observation was obtained.

### Assessment of gastric peristalsis

Gastric peristalsis was classified into three grades as follows: none: no or very weak peristaltic waves are formed, but the movement does not show strong contraction; mild: pronounced peristaltic waves are formed in the antrum and reaches the pyloric ring, but observation is performed without interference of standard EGD screening; severe: peristaltic waves are deep and pronounced and proceed strangulating the antrum, so precise observation is difficult.

### Comparison of the costs of anti-peristaltic drugs

The total cost of anti-peristaltic premedication was compared between L-menthol and conventional drugs. The costs of L-menthol (Minclea<sup>®</sup>), hyoscine-N-butylbomide (Buscopan<sup>®</sup>; Nippon Boehringer Ingelheim Co., Ltd, Tokyo, Japan) and glucagon (Glucagon G Novo<sup>®</sup>; Novo Nordisk Pharma Ltd, Tokyo, Japan) converted from Japanese yen to U.S. dollars according to the annual average exchange rate in 2011 are \$10.77, \$0.79 and \$33.06, respectively.

### Statistical methods

The Chi-square test or one-way analysis of variance (ANOVA) were used to evaluate the differences.  $P < 0.05$  was considered to be statistically significant.

## Results

A total of 173 patients were enrolled in this study, including 104 males and 69 females with a median age of 62 years (range: 34-86 years). Hyoscine-N-butylbomide

was contraindicated in 28 patients due to severe heart disease, prostatic hypertrophy or narrow angle glaucoma.

The rate of peristaltic grade observed without the use of any anti-peristaltic drugs is presented in Fig. 2. The peristaltic grade was none or mild in 88.5% of the patients. The grade was severe in 11.6% of the patients, and L-menthol was sprayed in this group. No significant differences were found in age or sex between each grade in the first assessment (Table 1). After spraying L-menthol, the proportion of subjects with severe peristalsis was 0.0% and EGD screening was continued satisfactorily (Fig. 2). The mean time from spraying L-menthol to the disappearance of peristalsis was  $25.50 \pm 13.87$  seconds. No adverse effects caused by L-menthol were observed during or after EGD.

Next, we evaluated the costs of the anti-peristaltic drugs, comparing two anti-peristaltic strategies for endoscopic examination e.g. the strategy with L-menthol usage during endoscopy only when necessary vs. that with routine hyoscine-N-butylbomide or glucagon usage before endoscopy. In this study, L-menthol was used in 20 patients; therefore, the total cost was \$215.40. If we had injected hyoscine-N-butylbomide or glucagon routinely in the patients enrolled in this study, hyoscine-N-butylbomide would have been administered to 145 patients and glucagon would have been administered to 28 patients with contraindications to hyoscine-N-butylbomide. Therefore, in this condition, the total cost would have been \$1,040.23 (Table 2).

## Discussion

In Japan, anti-peristaltic drugs such as hyoscine-N-butylbomide and glucagon are routinely administered intramuscularly or intravenously immediately prior to performing EGD. The use of these drugs sometimes induces serious side effects. The administration of hyoscine-N-butylbomide is contraindicated for patients with diseases such as severe heart disease, prostatic hypertrophy or narrow angle glaucoma<sup>3)</sup>. Glucagon can cause delayed hypoglycemia<sup>4,5)</sup> and is costly.

Peppermint oil and L-menthol have been demonstrated to be useful anti-peristaltic agents for colonoscopy, barium enemas and ERCP<sup>6-10)</sup>. Treatment of irritable

(4)

## On-demand use of L-menthol in EGD

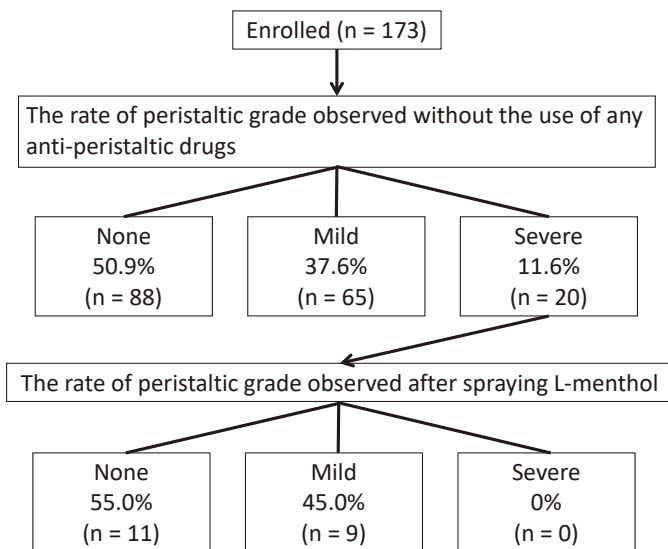


Fig. 2. The rate of peristaltic grade

None : no or very weak peristaltic waves are formed.

Mild : circular peristaltic waves are formed in the antrum without any interference of EGD screening.

Severe : impossible to achieve a precise observation due to the presence of peristaltic waves.

Table 1. Characteristics of the patients in the three peristaltic grade groups classified without the use of any anti-peristaltic drugs.

	None	Mild	Severe	<i>P</i> value
Number of patients	88	65	20	
Age (years)	62.1 ± 11.3	62.6 ± 10.9	64.5 ± 13.3	Not significant*
Male/female	56/32	35/30	13/7	Not significant**

\*One-way analysis of variance

\*\*Chi-square test

Table 2. Evaluation of cost-effectiveness

L-menthol (Minclea <sup>®</sup> ) was used in 20 patients in this study.
Total cost : \$10.77 × 20 patients = \$215.40
If we had injected hyoscine-N-butylbomide (Buscopan <sup>®</sup> ) or glucagon (Glucagon G Novo <sup>®</sup> ) routinely in the patients enrolled in this study,
Total cost : \$0.79 × 145 patients + \$33.06 × 28 patients (contraindications to hyoscine-N-butylbomide) = \$1,040.23

bowel syndrome with peppermint oil has been attempted<sup>11,12)</sup>. These substances relax GI smooth muscles *in vitro* by blocking the entry of calcium ions into GI smooth muscle cells<sup>13,14)</sup>. Recently, Hiki *et al.*<sup>15)</sup> reported that intragastric spraying of L-menthol significantly suppresses gastric peristalsis during endoscopic examinations compared with a placebo. In response to this, an L-menthol-based anti-peristaltic agent (Minclea<sup>®</sup>) created for use during EGD came onto the market in Japan in 2011.

Hiki *et al.* reported that, in their study, the proportion of subjects with none or mild peristalsis was 46.8% before spraying L-menthol<sup>16)</sup>. Hedenbro *et al.*<sup>17)</sup> reported that, among 235 patients undergoing EGD who were randomized to receive either i.v. scopolamine and a transdermal placebo, an i.v. placebo and a transdermal placebo or an i.v. placebo and transdermal scopolamine, no differences were observed between the groups with respect to the quality of diagnostic EGD. Considering these reports, we question the routine use of anti-peristaltic drugs for EGD. In this study, EGD was performed without the use of any anti-peristaltic drugs, and a precise observation was obtained without interference of peristalsis in 88.5% of the patients.

Since L-menthol is directly sprayed onto the gastric mucosa through a biopsy channel of the endoscope, it is easy to administer L-menthol after assessing the degree of gastric peristalsis. We sprayed L-menthol only when obtaining a precise observation was difficult due to the presence of severe peristalsis. Gastric peristalsis was suppressed after spraying in all patients. It is therefore unnecessary to routinely use anti-peristaltic agents in all cases.

The proportion of elderly persons in the Japanese population is rapidly increasing. The numbers of elderly patients with underlying diseases and those with contraindications to anticholinergic agents are expected to increase in the future. Umegaki *et al.*<sup>1)</sup> analyzed background factors among 1,480 subjects undergoing EGD using questionnaires. In their report, more than half of the elderly subjects had contraindications to anti-peristaltic drugs, and this rate was significantly higher among the elderly than in those aged less than 65 years. Few adverse effects have been reported for L-menthol, and its administration is noninvasive. Asao *et al.*<sup>7)</sup> evaluated

a total of 409 patients who underwent total colonoscopy with intraluminal administration of a peppermint solution, and no adverse effects were observed during or after colonoscopy. Hiki *et al.*<sup>16)</sup> applied L-menthol in 112 subjects undergoing EGD, and the only adverse drug reactions were diarrhea (3.5%) and increase blood amylase (0.9%), all of which were mild. The subgroup analyses revealed that the adverse effects were not related to the advanced age of the subjects<sup>16)</sup>. Hypersensitivity to L-menthol is an only contraindication. L-menthol might be safer than conventional antispasmodic agents in elderly patients. Furthermore, we demonstrated that selective administration of L-menthol is less expensive than conventional administration of anti-peristaltic agents.

In this study, we performed EGD screening without the use of anti-peristaltic premedication. The demerits of not using anti-peristaltic premedication have not been reported. This study was a non-randomized prospective study conducted to examine whether performing EGD without the administration of anti-peristaltic drugs is associated with unfavorable effects. Therefore, it is not possible to conclude from our results that performing EGD without the use of anti-peristaltic premedication is beneficial or that performing EGD with anti-peristaltic premedication has an advantage. In order to evaluate the effects of the use of anti-peristaltic drugs statistically, a randomized controlled trial must be conducted. Considering the rate of adverse events associated with conventional anti-peristaltic drugs, a number of patients would need to be enrolled in order to evaluate the superiority or inferiority of the use of anti-peristaltic drugs for EGD screening. In fact, achieving complete suppression of gastric peristalsis is not always necessary to perform EGD, and the clinical relevance determined from such a randomized controlled study might not be that significant. Considering the complications, it is advisable to avoid the use of these drugs in cases of satisfactory observation. We have shown that EGD screening can be performed in many cases without the use of any peristaltic drugs.

In conclusion, the use of routine premedication with hyoscine-N-butylbomide or glucagon as anti-peristaltic drugs for EGD screening may be unnecessary. When severe peristalsis interferes with obtaining a precise ob-

ervation, the use of L-menthol instead of hyoscine-N-butylbomide or glucagon is easy, sufficient and less expensive.

### References

- 1) Umegaki, E., Abe, S., Tokioka, S., Takeuchi, N., Takeuchi, T., Yoda, Y., Murano, M. and Higuchi, K. (2010) Risk management for gastrointestinal endoscopy in elderly patients : questionnaire for patients undergoing gastrointestinal endoscopy. *J. Clin. Biochem. Nutr.*, **46**, 73-80.
- 2) Treweek, P. and Barrett, N.K. (1987) Allergic reaction to Buscopan. *Br. J. Radiol.*, **60**, 417-418.
- 3) Fink, A.M. and Aylward, G.W. (1995) Buscopan and glaucoma : a survey of current practice. *Clin. Radiol.*, **50**, 160-164.
- 4) Hashimoto, T., Adachi, K., Ishimura, N., Hirakawa, K., Katsube, T., Kurotani, A., Hattori, S. and Kinoshita, Y. (2002) Safety and efficacy of glucagon as a premedication for upper gastrointestinal endoscopy—a comparative study with butyl scopolamine bromide. *Aliment. Pharmacol. Ther.*, **16**, 111-118.
- 5) Sugase, T., Nonaka, K., Yoshida, T., Morishita, S., Toyoshima, H., Tarui, S. and Shima, K. (1976) Comparison of the changes in plasma human growth hormone (HGH) and immuno-reactive glucagon (IRG) after intravenous and subcutaneous injection of glucagon. *Endocrinol. Jpn.*, **23**, 187-193.
- 6) Leicester, R.J. and Hunt, R.H. (1982) Peppermint oil to reduce colonic spasm during endoscopy. *Lancet*, **2**, 989.
- 7) Asao, T., Mochiki, E., Suzuki, H., Nakamura, J., Hirayama, I., Morinaga, N., Shoji, H., Shitara, Y. and Kuwano, H. (2001) An easy method for the intraluminal administration of peppermint oil before colonoscopy and its effectiveness in reducing colonic spasm. *Gastrointest. Endosc.*, **53**, 172-177.
- 8) Sparks, M.J., O'Sullivan, P., Herrington, A.A. and Morcos, S.K. (1995) Does peppermint oil relieve spasm during barium enema ? *Br. J. Radiol.*, **68**, 841-843.
- 9) Asao, T., Kuwano, H., Ide, M., Hirayama, I., Nakamura, J.I., Fujita, K.I. and Horiuti, R. (2003) Spasmolytic effect of peppermint oil in barium during double-contrast barium enema compared with Buscopan. *Clin. Radiol.*, **58**, 301-305.
- 10) Yamamoto, N., Nakai, Y., Sasahira, N., *et al.* (2006) Efficacy of peppermint oil as an antispasmodic during endoscopic retrograde cholangiopancreatography. *J. Gastroenterol. Hepatol.*, **21**, 1394-1398.
- 11) Rees, W.D., Evans, B.K. and Rhodes, J. (1979) Treating irritable bowel syndrome with peppermint oil. *Br. Med. J.*, **2**, 835-836.
- 12) Pittler, M.H. and Ernst, E. (1998) Peppermint oil for irritable bowel syndrome : a critical review and metaanalysis. *Am. J. Gastroenterol.*, **93**, 1131-1135.
- 13) Hawthorn, M., Ferrante, J., Luchowski, E., Rutledge, A., Wei, X.Y. and Triggle, D.J. (1988) The actions of peppermint oil and menthol on calcium channel dependent processes in intestinal, neuronal and cardiac preparations. *Aliment. Pharmacol. Ther.*, **2**, 101-118.
- 14) Hills, J.M. and Aaronson, P.I. (1991) The mechanism of action of peppermint oil on gastrointestinal smooth muscle. An analysis using patch clamp electrophysiology and isolated tissue pharmacology in rabbit and guinea pig. *Gastroenterology*, **101**, 55-65.
- 15) Hiki, N., Kaminishi, M., Yasuda, K., *et al.* (2011) Antiperistaltic effect and safety of L-menthol sprayed on the gastric mucosa for upper GI endoscopy : a phase III, multicenter, randomized, double-blind, placebo-controlled study. *Gastrointest. Endosc.*, **73**, 932-941.
- 16) Hiki, N., Kaminishi, M., Tanabe, S., *et al.* (2011) An open-label, single-arm study assessing the efficacy and safety of L-menthol sprayed onto the gastric mucosa during upper gastrointestinal endoscopy. *J. Gastroenterol.*, **46**, 873-882.
- 17) Hedenbro, J.L., Frederiksen, S.G. and Lindblom, A. (1991) Anticholinergic medication in diagnostic endoscopy of the upper gastrointestinal tract. *Endoscopy*, **23**, 199-202.