

ACOUSTIC RADIATION FORCE IMPULSE ELASTOGRAPHY FOR THE DIFFERENTIAL DIAGNOSIS OF LIVER TUMORS IN PATIENTS WITH LIVER DYSFUNCTION

Mitsuru Chiba, Takashi Goto, Shigetoshi Ohshima, Kouichi Miura, Tomomi Shibuya, Wataru Sato, Takahiro Dohmen, Masanari Sekine, Ryo Kanata, Toshitaka Sakai, Shinichiro Minami, Akashi Fujita and Hirohide Ohnishi

(received 19 January 2015, accepted 4 March 2015)

Department of Gastroenterology Akita University Graduate School of Medicine

Abstract

Objective : Acoustic radiation force impulse (ARFI) technology can measure the elasticity of tissue and tumor. The aim of this study was to evaluate whether the ARFI technology can differentiate cavernous hemangioma, hepatocellular carcinoma (HCC) and metastatic liver tumors in patients with liver dysfunction.

Materials and Methods : Forty patients with liver dysfunction and liver tumors were enrolled in the study. The shear wave velocities (SWVs) in the tumors and background liver were examined by ARFI elastography under ultrasonography (US).

Results : The SWVs in livers bearing HCCs were significantly higher than those of livers bearing cavernous hemangiomas. The SWVs in HCCs and metastatic liver tumors were significantly higher than those in cavernous hemangiomas. The SWVs in metastatic liver tumors were significantly higher than those in HCCs. The SWV ratio of metastatic liver tumor/parenchyma was significantly higher than that of cavernous hemangioma/parenchyma and HCC/parenchyma. There was a significant correlation between the tumor sizes and the SWVs in metastatic liver tumors.

Conclusions : We herein demonstrated that ARFI elastography could noninvasively provide helpful information, without the need for biopsy, that could be used for the differential diagnosis among cavernous hemangiomas, HCCs and metastatic liver tumors in patients with liver dysfunction.

Key words : Acoustic radiation force impulse, shear waves velocity, hepatocellular carcinoma, cavernous hemangioma, metastatic liver tumor

Introduction

Clinicians sometimes encounter solid focal lesions during in conventional ultrasonography (US) when examining a patient with liver dysfunction. Although the good

spatial resolution of conventional US ensures high sensitivity in detecting focal liver lesions, the technique has less capability for characterizing small lesions, particularly in the cirrhotic liver¹⁾. The most frequently encountered benign lesion is hemangioma, with a prevalence of 7-21%²⁾. The characteristic US findings of hemangioma are well known, but some malignant hepatic tumors have US findings that are similar to those of hemangiomas³⁾. It has been estimated that 20-25% of patients with known solid malignant tumors have liver metastasis at the time of diagnosis²⁾. However, the appearance of

Corresponding author : Takashi Goto
Department of Gastroenterology, Akita University Graduate School of Medicine, 1-1-1 Hondo, Akita, 010-8543 Japan
TEL : 81-18-834-1111
FAX : 81-18-836-2611
E-mail : takashi@doc.med.akita-u.ac.jp

metastatic liver tumors in conventional US varies⁴⁾. In the clinical setting, it is very difficult to differentially diagnose liver tumors by conventional US in the patients with various causes of liver dysfunction.

To differentially diagnose solid focal lesions in the liver, a histological examination by liver biopsy is the gold standard. However, a liver biopsy is invasive, and is associated with the possibility of seeding in the case of malignant tumors. To differentiate these solid lesions, we typically examine patients by contrast-enhanced multidetector-row computed tomography (CE-MDCT), gadolinium-ethoxybenzyl-diethylenetriamine pentaacetic acid (Gd-EOB-DTPA)-enhanced magnetic resonance imaging (MRI) or contrast-enhanced ultrasonography (CE-US)⁵⁾. The specific features of the contrast medium provide important information for the diagnosis. However, it is not possible to use contrast medium in patients with contrast allergies or who have complications or comorbidities that prevent them from undergoing these examinations. The additional information provided by conventional US performed simultaneously with other examination without contrast medium is invaluable for the differential diagnosis in such cases.

Recently, the acoustic radiation force impulse (ARFI) technology has been shown to be able to measure the elasticity of tissue⁶⁾. The ARFI technology uses an acoustic push pulse, followed by a detection pulse, to calculate the shear wave velocity (SWV; m/s) of the tissue. The SWV increases with tissue stiffness⁷⁾. It is possible to analyze the tissue stiffness simultaneously by conventional US without the need for a liver biopsy. Recent studies have reported that ARFI imaging can be used to determine the elasticity of the tissue in patients with chronic hepatic diseases, such as chronic hepatitis C and nonalcoholic steatohepatitis⁸⁻¹⁰⁾. In addition, the ARFI technology with Virtual Touch tissue quantification (VTTQ) could non-invasively provide significant complementary information regarding the differential diagnosis of focal solid liver lesions¹¹⁾. ARFI uses short-duration acoustic pulses generated from a probe under real-time B-mode imaging to produce localized displacements in tissue. Because ARFI uses elastography with a flexible metering box on the region of interest (ROI), it is possible to apply the ARFI technology to elastography for the

tumor and liver without the need for external compression^{12,13)}. To date, there have been several papers that have evaluated the usefulness of ARFI elastography in the evaluation of liver tumors^{3,11,14-17)}.

The aim of the present study was to evaluate whether the ARFI technology can differentiate cavernous hemangioma, hepatocellular carcinoma (HCC) and metastatic liver tumors in patients with liver dysfunction.

Materials and Methods

Patients

From February 2010 to April 2013, a total of 40 patients with liver dysfunction and liver tumors that were visualized on conventional US were enrolled in this study. The diagnosis of these liver tumors was confirmed by CE-MDCT, Gd-EOB-DTPA-enhanced MRI and/or US-guided tumor biopsy. On CE-MDCT, HCCs reveal hyperenhancement in the arterial phase and wash out in the portal venous phase, cavernous hemangiomas reveal progressive, peripheral nodular enhancement of the lesion with centripetal fill in, and then, metastatic liver tumors reveal a variety of enhancement by the primary tumor¹⁸⁾. On Gd-EOBMRI, HCCs reveal intense enhancement in the arterial phase and low signal intensity in the hepatocellular phase, cavernous hemangiomas reveal peripheral nodular enhancement with central progression, and then, metastatic liver tumors generally reveal no enhancement in the hepatocellular phase¹⁹⁾. We obtained informed consent from all patients before their enrollment in this study. The study was conducted in accordance with the Declaration of Helsinki.

Analysis of the SWV

All patients underwent conventional B-mode US and ARFI elastography using a Siemens Acuson S2000 (Mochida Siemens Medical Systems Co. Ltd., Tokyo, Japan). On a B-mode US image, the elastic properties of the lesion to be analyzed were identified utilizing a ROI, characterized by a box with dimension of 10 mm × 5 mm. The ROI included the entire lesion to a maximum depth of 80 mm, without including any blood vessels or bile duct structures. In the measurement of the large tumor, we measured SWV at the homogenous part

of the tumor not to comprise necrotic portion. Measurements of the surrounding parenchyma were also performed with the upper limit of the ROI within 10–20 mm from the surface of the liver, also without the inclusion of any vascular or biliary structures. The SWVs from the liver tumor and the surrounding parenchyma were calculated as the average value of six trials (m/s).

Fig. 1 shows the measurement of the SWV in cavernous hemangioma. CT scans showed typical cavernous hemangioma in the arterial phase, the portal phase and the post-vascular phase. Fig. 2 shows the measurement of the SWV in HCC. CT scans showed the enhancement of the tumor in the arterial phase and washout of the contrast medium in the portal phase. Fig. 3 shows the measurement of the SWV in metastatic liver tumor. CT scans showed a low density area in the portal phase.

Statistical analysis

The values are expressed as the means \pm standard de-

viation. Variables were analyzed using the Mann-Whitney U-test. The correlation between the SWVs in the liver tumors and the tumor size were analyzed by Spearman's rank correlation coefficient. A p-value <0.05 was considered to be statistically significant.

Results

Characteristics of the patients and tumors

Thirteen patients (two males and 11 females; average age, 58.0 ± 15.2 years) had cavernous hemangiomas, 19 (13 males and six females; average age, 70.8 ± 10.8 years) had HCCs and eight (seven males and one female; average age, 62.6 ± 9.6 years) had metastatic liver tumors. The mean diameter of cavernous hemangiomas was 26.8 ± 23.4 mm, that of the HCCs was 29.3 ± 25.9 mm and that of the metastatic liver tumors was 63.3 ± 48.7 mm. In the cavernous hemangiomas, eight cases (61.5%) had chronic hepatitis (HCV, five cases; HBV, three cases), and five cases (38.5%) had a

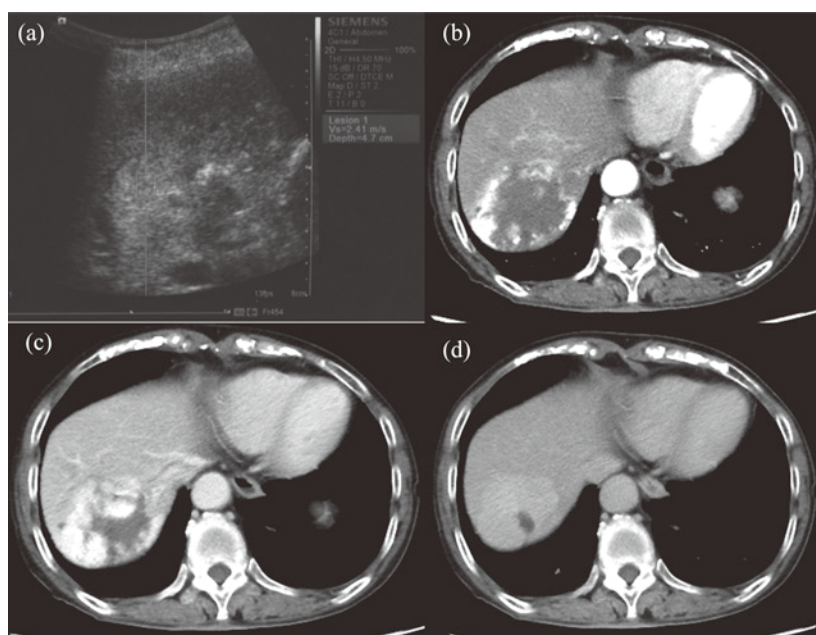


Fig. 1. The measurement of the acoustic radiation force impulse value within the region of interest of cavernous hemangiomas. The SWV was measured when the region of interest box was placed within the cavernous hemangioma. (a) The measurement of the SWV, (b) CT scans in the arterial phase, (c) CT scans in the portal phase, (d) CT scans in the post-vascular phase.

(22)

ARFI elastography for liver tumors

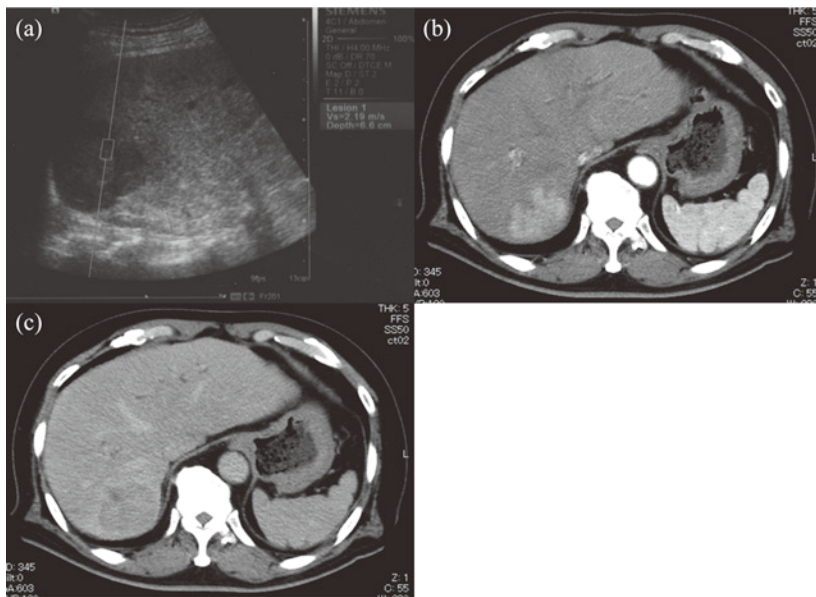


Fig. 2. The measurement of the acoustic radiation force impulse value within the region of interest of HCC. The SWV was measured when the region of interest box was placed within the HCC. (a) The measurement of the SWV, (b) CT scans in the arterial phase, (c) CT scans in the portal phase.

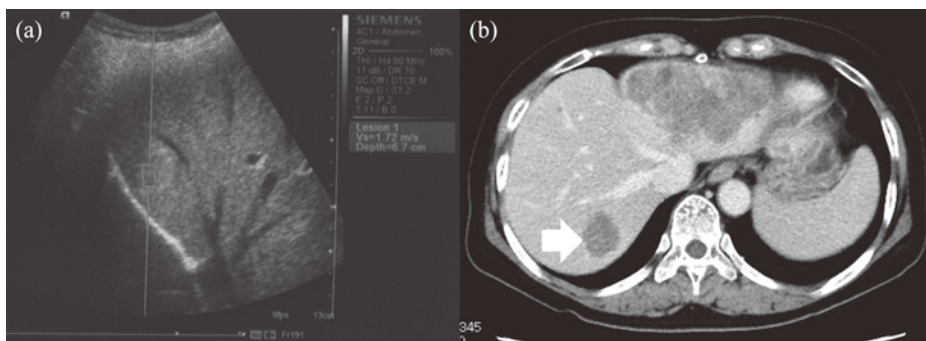


Fig. 3. The measurement of the acoustic radiation force impulse value within the region of interest of metastatic liver tumors. The SWV was measured when the region of interest box was placed within the metastatic liver tumor. (a) The measurement of the SWV, (b) CT scans in the portal phase.

fatty liver. In the HCC patients, 16 (84.2%) had liver cirrhosis (HCV, 12 cases ; HBV, one case ; alcoholic, one case ; non-alcoholic steatohepatitis, one case and non-HBV non-HCV, one case) and three cases (15.8%) had viral chronic hepatitis (HCV, two cases ; HBV, one case). In the patients with metastatic liver tumors, one (12.5%) had liver cirrhosis due to HCV, one (12.5%) had a fatty liver and six (75.0%) had liver dysfunction of unknown

cause (non-HBV non-HCV) (Table 1).

The SWVs in the liver parenchyma

The mean SWVs in livers bearing cavernous hemangiomas, HCCs and metastatic liver tumors were 1.21 ± 0.37 m/s, 1.82 ± 0.49 m/s and 1.49 ± 0.39 m/s, respectively (Fig. 4). The mean SWV in the livers bearing HCCs was significantly higher than that of the livers bearing cavernous

Table 1. The characteristics of the patients and tumors

	Cavernous hemangioma	HCC	Metastatic liver tumor
number	13	19	8
age	58.0±15.2	70.8±10.8	62.6±9.6
male/female	2/11	13/6	7/1
tumor size(mm)	26.8±23.4	29.3±25.9	63.3±48.7
Cause of liver disease	CH(HCV) 5 CH(HBV) 3 fatty liver 5	LC(HCV) 12 LC(HBV) 1 LC(Alcohol) 1 LC(NASH) 1 LC(NBNC) 1 CH(HCV) 2 CH(HBV) 1	LC(HCV) 1 fatty liver 1 liver dysfunction (NBNC) 6

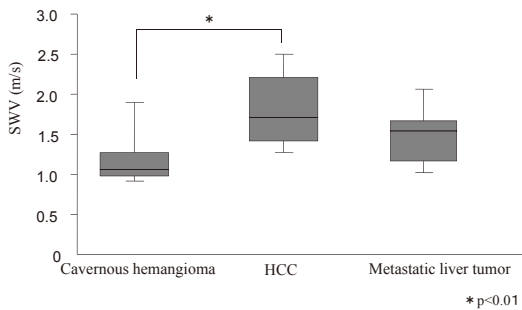


Fig. 4. The SWVs in the liver parenchyma.

hemangiomas ($p < 0.01$). There was no significant difference between the mean SWV in livers bearing cavernous hemangiomas and metastatic liver tumors, or between the mean SWVs in livers bearing HCCs and metastatic liver tumors.

The SWVs in the liver tumors

The mean SWVs in cavernous hemangiomas, HCCs and metastatic liver tumors were 1.39 ± 0.39 m/s, 2.24 ± 0.65 m/s and 3.04 ± 1.10 m/s, respectively (Fig. 5). The mean SWVs in HCCs and metastatic liver tumors were significantly higher than those in cavernous hemangiomas ($p < 0.01$). The mean SWVs in metastatic liver tumors were significantly higher than those in HCCs ($p < 0.05$).

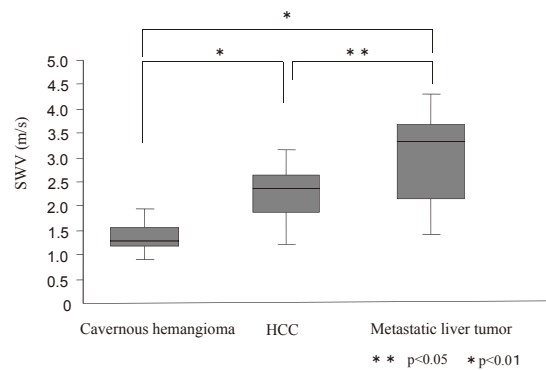


Fig. 5. The SWVs in the liver tumors.

The SWV ratios of the liver tumor/the surrounding parenchyma

The SWV ratios of the liver tumor to the surrounding parenchyma in cavernous hemangiomas, HCCs and metastatic liver tumors were 1.23 ± 0.49 , 1.33 ± 0.63 and 2.04 ± 0.66 , respectively (Fig. 6). The SWV ratio of the metastatic liver tumor/parenchyma was significantly higher than those of a cavernous hemangioma/parenchyma and HCC/parenchyma.

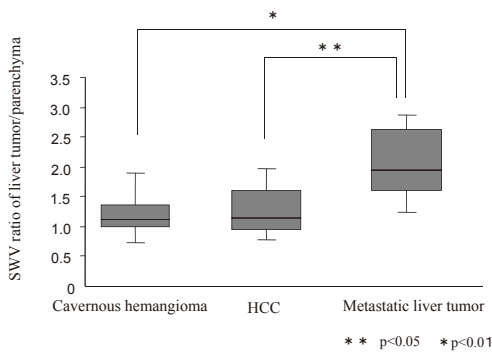


Fig. 6. The SWV ratios of the liver tumor/the surrounding parenchyma.

The correlation between the tumor sizes and the SWV in the liver tumors

There was a significant correlation between the tumor sizes and the SWVs in metastatic liver tumors (correlation coefficient : 0.786, $n=8$, $p=0.038$), but there were

no correlations between the tumor sizes and the SWVs in the liver tumors in patients with cavernous hemangiomas (correlation coefficient : 0.353, $n=13$, $p=0.244$) and HCCs (correlation coefficient : -0.026 , $n=19$, $p=0.896$) (Fig. 7).

Discussion

The standard medical examinations for patients with liver dysfunction are blood chemical analyses and conventional US examinations. When we find solid focal lesions during conventional US, ARFI elastography can measure the SWVs in both the liver parenchyma and liver tumor simultaneously. In the present study, the mean SWVs in livers bearing HCC were significantly higher than those in cavernous hemangiomas. Most HCC patients have progressive chronic hepatic disease. In fact, of the 19 HCC patients, 16 had liver cirrhosis and three cases had chronic hepatitis. In the 13 cavernous hemangiomas, eight cases had chronic hepatitis, and five cas-

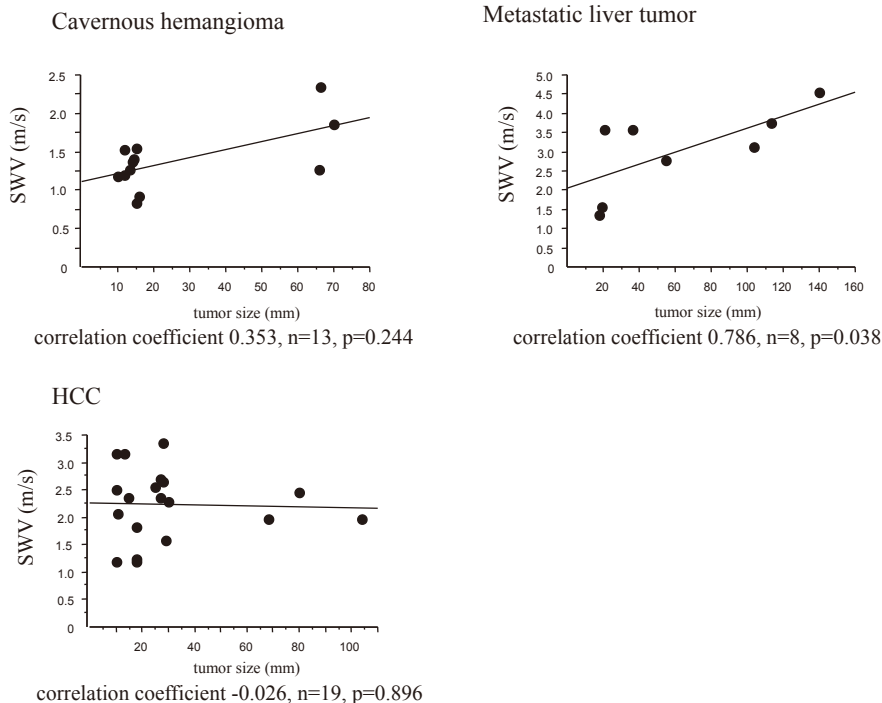


Fig. 7. The correlation between the SWVs in the liver tumors and the tumor size.

es had a fatty liver. Among the patients with liver dysfunction, the patients with HCC had more progressive liver disease than those with cavernous hemangiomas.

There was no significant difference between the mean SWVs in livers bearing cavernous hemangiomas and metastatic liver tumors, or between the mean SWVs in livers bearing HCCs and metastatic liver tumors. In the eight metastatic liver tumors, one patient had liver cirrhosis due to HCV, one had a fatty liver and six had liver dysfunction of an unknown cause (non-HBV non-HCV). In the patients with metastatic liver tumors, the progression of liver disease was diverse. The mean SWV in the liver parenchyma may be useful to estimate the background liver condition of the liver tumor.

The SWV in the liver tumor directly indicates the characteristics of the tumor. Since Fahey et al. first reported the usefulness of ARFI elastography for evaluating liver tumors¹⁴⁾, the clinical application of ARFI elastography has expanded from the assessment of liver fibrosis to the differential diagnosis of liver tumors. ARFI elastography has obvious superiority over other techniques, because it can be added to conventional US examinations, and can be performed regardless of the presence of impediments such as ascites and pleural effusion.

We herein compared the quantitative SWVs of cavernous hemangiomas, HCCs and metastatic liver tumors, and demonstrated that the stiffness of HCCs is greater than that of cavernous hemangiomas, which are benign liver tumors. In addition, metastatic liver tumors were stiffer than HCCs. Our data are consistent with several previous reports that showed that malignant tumors were stiffer than benign tumors^{3,15,16)}.

The mean SWVs in the HCCs in the present study and four other studies^{3,11,15,17)} were 2.20 m/s, 2.17 m/s, 2.45 m/s, 2.31 m/s and 2.40 m/s, respectively. The SWVs in HCCs were similar among these studies. The stiffness of HCCs may be comparatively uniform. Some HCCs had low SWVs and it can be difficult to differentiate these cases from the cavernous hemangiomas. The SWVs in HCCs might be affected from the differentiation, vascularity, the fatty change in the tumor, and tumor size. But in the present study, there was no correlation between the SWVs and tumor size in HCCs. Further studies are

warranted to investigate the relation between SWVs in HCC and pathologic construction.

However, the mean SWVs in the cavernous hemangiomas in the present study and five other studies^{3,11,15-17)} were 1.37 m/s, 2.30 m/s, 1.51 m/s, 1.35 m/s, 1.80 m/s and 2.14 m/s, respectively. There were some discrepancies among these studies. One of the possible reasons is the heterogeneity of the tissue in cavernous hemangiomas. Cavernous hemangiomas are composed of various tissues, including fibrous septae, vascular thrombi and focal stromal calcification³⁾. Therefore, several different areas should be measured in cavernous hemangiomas.

The mean SWVs in the metastatic liver tumors in the present study and three other studies^{11,16,17)} were 3.28 m/s, 2.87 m/s, 4.23 m/s and 3.0 m/s, respectively. The SWVs in metastatic liver tumors had a tendency to have high values. Based on our data, the SWV ratio of the metastatic liver tumor/parenchyma was significantly higher than those of cavernous hemangioma/parenchyma and HCC/parenchyma. The differences between the SWVs in liver tumors and the surrounding parenchyma were most conspicuous in the cases with metastatic liver tumors. Comparing the SWVs of liver tumors and the surrounding parenchyma may be helpful to differentially diagnose metastatic liver tumors.

Davies et al. reported that there was no correlation between the SWVs and liver tumor size in cavernous hemangiomas and metastatic liver tumors¹⁶⁾. In contrast, there was a significant correlation between the SWVs and tumor sizes in the metastatic liver tumors in our study. The SWVs of metastatic liver tumors may reflect the characteristics of the primary tumors, because metastatic liver tumors vary in vascularity and in the density of the primary tumors. For example, Kim et al. reported that the SWV in colon cancer metastases was 3.70 m/s, while that of other metastasis was 2.82 m/s³⁾. In our study, the primary tumors of the eight metastatic liver tumors included urinary bladder cancer, renal cell carcinoma, bile duct cancer, malignant lymphoma, pancreatic cancer (two cases) and colon cancer (two cases). The consistency of the liver tumor depends on the ratio of cancer cells to fibrous stroma²⁰⁾. The SWVs of metastatic liver tumors may therefore reflect the changes in the tissue composition, with the extent of cancer cells

and fibrous stroma closely associated with the tumor size. Further studies are warranted to determine the stiffness of each metastatic liver tumor type.

We herein demonstrated that ARFI elastography could noninvasively provide helpful information at the same time as conventional US, without the need for a biopsy or contrast medium, and this information could be used for the differential diagnosis among cavernous hemangiomas, HCCs and metastatic liver tumors in patients with liver dysfunction.

References

- 1) D'Onofrio, M., Faccioli, N., Zamboni, G., Malagò, R., Caffarri, S., Fattovich, G. and Mucelli, R.P. (2008) Focal liver lesions in cirrhosis : value of contrast-enhanced ultrasonography compared with Doppler ultrasound and α -fetoprotein levels. *Radiol. Med.*, **113**, 978-991.
- 2) Ariff, B., Lloyd, C.R., Khan, S., Shariff, M., Thillainayagam, A.V., Bansi, D.S., Khan, S.A., Taylor-Robinson, S.D. and Lim, A.K. (2009) Imaging of liver cancer. *World. J. Gastroenterol.*, **15**, 1289-1300.
- 3) Kim, J.E., Lee, J.Y., Bae, K.S., Han, J.K. and Choi, B.I. (2013) Acoustic Radiation force impulse elastography for focal hepatic tumors : usefulness for differentiating hemangiomas from malignant tumors. *Korean. J. Radiol.*, **14**, 743-753.
- 4) Jang, J.Y., Kim, M.Y., Jeong, S.W., *et al.* (2013) Current consensus and guidelines of contrast enhanced ultrasound for the characterization of focal liver lesions. *Clin. Mol. Hepatol.*, **19**, 1-16.
- 5) Bota, S., Piscaglia, F., Marinelli, S., Pecorelli, A., Terzi, E. and Bolondi, L. (2012) Comparison of international guidelines for noninvasive diagnosis of hepatocellular carcinoma. *Liver Cancer*, **1**, 190-200.
- 6) Nightingale, K., Nightingale, R., Stutz, D. and Trahey, G. (2002) Acoustic radiation force impulse imaging of in vivo vastus medialis muscle under varying isometric load. *Ultrason. Imaging*, **24**, 100-108.
- 7) Nightingale, K. (2011) Acoustic radiation force impulse (ARFI) imaging : a review. *Curr. Med. Imaging Rev.*, **7**, 328-339.
- 8) Nishikawa, T., Hashimoto, S., Kawabe, N., *et al.* (2014) Factors correlating with acoustic radiation force impulse elastography in chronic hepatitis C. *World Journal of Gastroenterology*, **20**, 1289-1297.
- 9) Carmen, F.B., Dan, A., Radu, U., Dragos, C., Cristian, B. and Gabriela, M. (2009) Acoustic radiation force imaging sonoelastography for noninvasive staging of liver fibrosis. *World Journal of Gastroenterology*, **15**, 5525-5532.
- 10) Osaki, A., Kubota, T., Suda, T., *et al.* (2010) Shear wave velocity is a useful marker for managing nonalcoholic steatohepatitis. *World Journal of Gastroenterology*, **16**, 2918-2925.
- 11) Gallotti, A., D'Onofrio, M., Romanini, L., Cantisani, V. and Pozzi, Mucelli, R. (2012) Acoustic Radiation Force Impulse (ARFI) ultrasound imaging of solid focal liver lesions. *European Journal of Radiology*, **81**, 451-455.
- 12) D'Onofrio, M., Gallotti, A. and Pozzi, Mucelli, R. (2010) Virtual Touch tissue quantification : measurement repeatability and normal values in the healthy liver. *AJR Am. J. Roentgenol.*, **195**, 132-136.
- 13) Friedrich-Rust, M., Wunder, K., Krienrer, S., *et al.* (2009) Liver fibrosis in viral hepatitis : noninvasive assessment with acoustic radiation force impulse imaging versus transient elastography. *Radiology*, **252**, 595-604.
- 14) Fahey, B.J., Nelson, R.C., Bradway, D.P., Hsu, S.J., Dumont, D.M. and Trahey, G.E. (2008) In vivo visualization of abdominal malignancies with acoustic radiation force elastography. *Phys. Med. Biol.*, **53**, 279-293.
- 15) Cho, S.H., Lee, J.Y., Han, J.K. and Choi, B.I. (2010) Acoustic radiation force impulse elastography for the evaluation of focal solid hepatic lesions : preliminary findings. *Ultrason. Med. Biol.*, **36**, 202-208.
- 16) Davis, G. and Koenen, M. (2011) Acoustic radiation force impulse elastography in distinguishing hepatic haemangiomas from metastases : preliminary observations. *Br. radiol.*, **84** : 939-943
- 17) Frulio, N., Laumonier, H., Carteret, T., Laurent, C., Marie, F., Balabaud, C., Bioulac-Sage, P. and Trillaud, H. (2013) Evaluation of liver tumors using acoustic radiation force impulse elastography and correlation with histologic data. *J. Ultrasound. Med.* **32**, 121-130
- 18) Kristina, Zvinien. (2012) Differential Diagnosis of Hepatocellular Carcinoma on Computed Tomography.

- Joseph W.Y. Lau. (ed.) *Hepatocellular Carcinoma-Clinical Research*. INTECH, Rijeka, pp. 105-138.
- 19) Jose, Traila., Campos, Claude, B. Sirlin and Jin-Young, Choi. (2012) Focal hepatic lesions in EOB-DTPA enhanced MRI : the atlas. Robert Hermans (ed.) *Insight into Imaging*. Springer, Berlin, pp. 451-474.
- 20) Sheila, Sherlock. and James, Dooley. (2002) Chapter 31 Malignant liver tumours. *Diseases of the liver and biliary system*. Eleven edition. Blackwell Science, London, pp. 537-561.