

COMPLICATIONS ENCOUNTERED WITH A TRANSFEMORALLY PLACED PORT-CATHETER SYSTEM FOR REGIONAL CHEMOTHERAPY OF HEPATOBIILIARY-PANCREATIC TUMORS

Joichi Heianna, Manabu Hashimoto²⁾, Takaharu Miyauchi, Satoshi Takahashi²⁾,
Osamu Watanabe²⁾, Etuko Tate²⁾, Masaru Sakusabe¹⁾, Hitoshi Seki¹⁾,
Shinichiro Ouchi¹⁾, Tsutomu Sato³⁾, Yuzo Yamamoto³⁾, Jiro Watarai²⁾

(Received 19 August 2004, Accepted 21 September 2004)

Department of Radiology and ¹⁾Surgery, Japanese Red Cross Akita Hospital, Akita 010-1495, Japan

²⁾Division of Radiology and Radiation Oncology, Department of Integrated Medicine and

*³⁾Division of Gastroenterological Surgery, Department of Surgery, Akita University School of
Medicine, Akita 010-8543, Japan*

Abstract

Purpose: To determine the rate of complications associated with a port-catheter system implanted via the femoral arterial access for hepatic arterial chemotherapeutic infusion.

Materials and Methods: One-hundred thirteen patients with liver metastases and primary hepato-biliarypancreatic tumors underwent the procedure. The infusion catheter was connected to a port implanted subcutaneously below the level of the inguinal ligament.

Results: Implantation of the system was successful in 107 of 113 patients (94.7%). We did not treat with infusion chemotherapy on 5 of 107 patients because of poor general condition. The observation period after placement ranged from 4 to 787 days (mean 233 days). Complications after system placement were observed in 18 of 102 patients (17.6%). These included hepatic arterial injury (7.8%) with a mean system use of 361 days (range 24-671 days), pocket trouble (4.9%) with a mean system use of 253 days (range 21-624 days), port-catheter system obstruction (3.9%) with a mean system use of 100 days (range 62-263 days) and significant catheter dislodgement from the target artery (2.9%) with a mean system use of 384 days (range 358-436 days).

Conclusion: Our data suggested that it was feasible and safe to place the port-catheter system percutaneously via the femoral artery.

Key words: Implanted port, Complication, Liver neoplasm, Chemotherapeutic infusion, Transfemoral

Introduction

Regional chemotherapy via the hepatic artery is a treatment option for patients with liver metastases

or primary hepato-biliary tumor. The rationale for arterial application of chemotherapeutic drugs is based on the fact that liver tumors or metastases derive their blood supply mainly from the hepatic

arteries, while the hepatic cells are also nourished via the portal vein¹⁾. Furthermore significantly higher response rates have been obtained compared to systemic treatment¹⁻³⁾. Due to higher extraction rates and first pass effect, the regional treatment shows reduced systemic side effects of applied drugs, which may be the most valuable argument for hepatic arterial infusion.

Drugs can be administered using a catheter inserted in the target artery with a subcutaneous implanted port-catheter system (PCS). For percutaneous placement of the PCS, two access routes are available: transsubclavian/brachial⁴⁻⁶⁾ and transfemoral⁷⁻⁹⁾. Stroke has been reported as a complication of the transsubclavian^{5,10,11)} or transbrachial approach¹²⁾. Hence we chose the transfemoral approach, together with a simple and effective method of implanting a PCS. We report the complications encountered during and after PCS implantation, and compare them with those reported for the subclavian (or brachial) artery approach.

Materials and Methods

Patients

One-handed thirteen patients (77 men and 36 women, aged 38-79 years, mean 63 years) with malignant hepatobiliary-pancreatic tumors were enrolled in this study. From January 2000 through August 2002, 107 percutaneously implantable PCSs were placed at the Department of Radiology, Akita University ($n=98$), and Red Cross Akita Hospital ($n=15$). In 55 patients the indication for PCS implantation was liver metastases (39 from colorectal carcinoma, 5 gastric cancer, 4 pancreatic cancer, 4 bile duct carcinoma, 1 gallbladder cancer, 1 cholangiocellular carcinoma, and 1 esophageal cancer). In 58 patients the indication was the presence of primary hepatobiliary-pancreatic tumors (27 cases of hepatocellular carcinoma, 18 pancreatic cancer, 7 cholangiocellular carcinoma, and 6 gallbladder cancer).

All patients were given detailed information about the procedure and written consent was

obtained.

Technical Procedure

The catheter used for permanent intravascular implantation was a commercially available 5 Fr heparin-coated polyurethane catheter (Anthon P-U catheter, Toray Medical Industries, Tokyo). The type of port was a MRI Port Low-Profile (Bard Access Systems, Salt Lake City, UT).

All procedures were performed under local anesthesia. After the right femoral artery was punctured with use of the Seldinger technique, the standard 4.2 Fr angiographic catheter (HANAKO Excellent EN, Hanako Medical Inc., Saitama) was advanced into the respective target vessel with fluoroscopic guidance, and visceral arteriography was performed to assess variant arterial supply. The final position of the catheter tip, and thereby the region of perfusion, was chosen according to the anatomy of each patient and the location of the lesions. Any vessels that presented a risk of gastrointestinal tract chemoperfusion were embolized if technically feasible. This usually included the gastroduodenal artery, the right gastric artery, and pancreatic branches. If a replaced right or left hepatic artery was present, it was also embolized. Embolization was performed with titanium 0.018 inch microcoils (Cook, Bloomington, IN) via a coaxially placed 3.0 Fr microcatheter (Microferet; Cook, Stouffville, Ontario Renegade; Boston, Natick, MA).

In our series, the vessels in which the catheter tip was positioned were the right gastroepiploic artery in 68 patients, the gastroduodenal artery in nine, the right hepatic artery in nine, the common hepatic artery in 10, the splenic artery in 14, and the celiac trunk in three. In the two former positions, an infusion catheter was placed with fixation by microcoils in the first 27 patients and without fixation in the remaining 50 patients. The four latter positions were used in patients with a ligature surgically placed on the gastroduodenal artery and tumor encasement of major vessels. In these cases, too, an infusion catheter was placed without fixation. In the two former positions, a side hole was opened in

the catheter at the origin of the proper hepatic artery for chemotherapeutic drugs to flow into the proper hepatic artery. In the cases in which the catheter was positioned in the splenic artery, a side hole was opened at the origin of the common hepatic artery. An infusion catheter was connected to a port implanted subcutaneously below the level

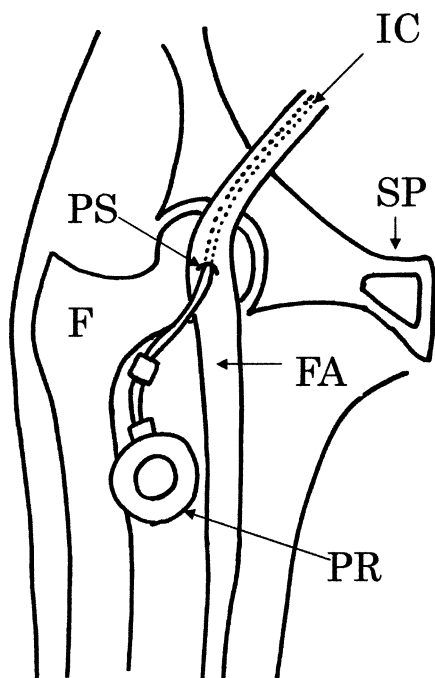


Fig.1 Frontal schematic depicts arrangement in the groin of components of the port-catheter system. F: femur FA: femoral artery IC: infusion catheter PR: port reservoir PS: puncture site SP: symphysis pubis

of the inguinal ligament through a subcutaneous tunnel (Fig. 1). Catheter position was checked by monthly abdominal radiography.

Regimens

The chemotherapy used in this study varied from patient to patient. For most patients, one of the two following combinations of drugs was chosen. For the first protocol, mitomycin C (3 or 6 mg/m²) was given on day 1 over 2 hours. This was followed by a 6-day continuous infusion of 5-fluorouracil (5-Fu; 165 or 330 mg/m²/day) on days 1 through 6. After this treatment, 330 mg/m² of 5-Fu was given over 2 to 4 hours every 1 or 2 weeks on an outpatient basis. For the second protocol, cisplatin (8 mg/m²/day) and 5-Fu (165 mg/m²/day) were given continuously for 5 days. This protocol was repeated for the initial 3 or 4 weeks. After this treatment, 165 or 330 mg/m² of 5-Fu was given over 2 to 4 hours every 1 or 2 weeks on an outpatient basis. These treatments were continued for as long as possible.

Results

Placement of the PCS was technically successful in 107 of 113 cases (94.7%). All technical success was obtained without evidence of immediate complications. Catheter placement was unsuccessful in three patients with severe tumor encasement of major vessels and in three with caudal tortuosity of the celiac trunk. Coil migration occurred during blood flow redistribution in one case; however, the patient did not experience peripheral occlusion

Table 1 Complications encountered during and after transfemoral port-catheter system for hepatic arterial chemotherapy infusion in 113 patients

	No. of complications (%)
During placement in 113 patients	
Embolization coil migration	1/113 (0.9)
After placement in 102 patients	
Complications around the groin	5/102 (4.9)
Other complications	13*/102 (12.7)

* Three of thirteen patients had two complications simultaneously.

(Table 1). No clinical symptoms occurred in relation to metallic coil occlusion of the gastroduodenal artery, right gastric artery, and pancreatic branches. We did not treat five of 107 patients with regional infusion chemotherapy because of their poor general condition. Ultimately, 102 patients were included in the analysis.

The observation period after placement ranged from 4 to 787 days (mean 233 days). Twelve patients continue to undergo regional chemotherapy with a patent and functioning catheter. In 90 patients the hepatic arterial chemotherapeutic infusion was broken off and their PCS was removed. It was removed in 59 because of neoplastic disease progression including of distant metastases, in 11 patients who asked surgeons for preoperative and/or postoperative withdrawal, in one patient who moved to another area, in one patient who refused chemotherapy, and in 18 patients who experienced PCS-related complications. All removal procedures were uncomplicated. The PCS could be easily withdrawn without peripheral embolization or damage to vessels or surrounding tissue.

Complications occurred in 18 of 102 patients (17.6%) (Table 2). The four most significant complications after placement were hepatic arterial injury (7.8%), pocket trouble (4.9%), port-catheter obstruction (3.9%) and significant catheter dislod-

gement from target artery (2.9%). All catheter dislodgement cases also experienced combined arterial occlusion.

Hepatic arterial injuries secondary to infusion catheter placement occurred in a total of eight cases (six occlusions and two vessel wall ulcerations) with a mean system use of 361 days (range 24-671 days). The former had no clinical symptoms but the latter suffered from severe abdominal pain only during drug infusion. In three of six occlusions, significant catheter dislodgement was also present (Fig. 2). In one of eight patients the PCS was replaced but the rest were removed because of difficulty in repositioning the catheter.

Port-pocket complications occurred in five cases (four infections and one hematoma) with a mean system use of 253 days (range 21-624 days). A case of pocket-hematoma underwent system replacement. Four cases of pocket-infections all underwent removal and treated with antibiotics.

PCS obstruction occurred in four cases with a mean system use of 100 days (range 62-263 days). Two cases underwent system replacement and the other two removal. We did not perform lytic therapy or mechanical recanalization with a guide wire because of a low success rate and their risky nature⁸⁾.

We experienced significant infusion catheter dis-

Table 2 Type of complications and treatment in 18 patients

Complication	Mean patency Time (days)	Type of treatment	No. of patients
Pocket trouble (<i>n</i> =5)	253	System removal and antibacterial treatment	4
		System replacement	1
Hepatic arterial injury (<i>n</i> =8)	361	System replacement	1
		System removal	7
Obstruction of the system (<i>n</i> =4)	100	System replacement	2
		System removal	2
Dislodgment of catheter (<i>n</i> =3)*	384	System replacement	1
		System removal	2
Chemotoxicity (<i>n</i> =1)	125	System removal	1

* All catheter dislodgement cases experienced hepatic arterial occlusions simultaneously.

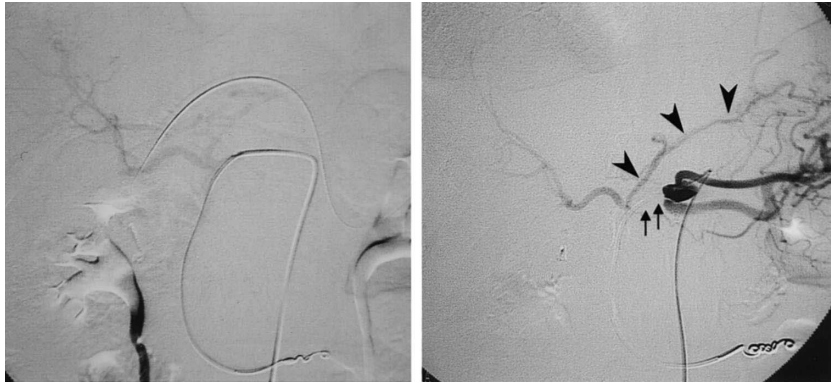

Fig. 2 A 56-year-old woman with metastatic liver tumors of pancreatic cancer. Left: The infusion catheter was positioned into the right gastroepiploic artery without fixation. The side hole of the catheter was opened at the level of the distal site of the common hepatic artery. Angiography through the infusion catheter showed good perfusion of bilateral hepatic lobes. Right: Four hundred thirty-six days after placement of the port-catheter system, the infusion catheter was dislodged by over 2.0 cm from the right gastroepiploic artery and the side hole of the catheter was in the celiac trunk. Angiography through the infusion catheter showed the occlusion of the common hepatic artery (arrow) and the left hepatic artery through left gastric artery (arrow head).

lodgement of over 2.0 cm from the target arteries in three patients with a mean system use of 384 days (range 358–436 days). One patient was given a new infusion catheter. In two of three cases the PCS was removed because of occlusion of the common hepatic artery.

Chmotoxicity included symptoms such as epigastria or back pain and peptic ulcer due to flow of anticancer drugs into accessory gastric arteries or pancreatic branches. One patient (0.9%) suffered from severe gastric ulcer believed to be induced by anticancer drugs. Since the patient did not request system replacement, the PCS was removed 125 days after placement.

None of the patients developed brain infarction. No patient reported restriction of motion or discomfort owing to the port-catheter system in the groin.

Discussion

Many institutions in Japan have adopted the left subclavian approach for port-catheter access^{4,5,11}. This choice, rather than femoral access, was made to cause less patient discomfort and to avoid bending of catheters in consequence of patients move-

ment. However, an emerging body of evidence suggests that there is an increased risk of brain infarction when using the left subclavian^{10,11,13}, or brachial approach¹². Minoyama *et al.* previously reported an associated 2.6% stroke rate in their experience of 114 patients with advanced hepatocellular carcinoma with a PCS implanted via the left brachial artery¹¹, whereas Head and Robboy reported a fatality related to an embolic stroke associated with left axillary arterial catheterization for diagnostic arteriogram¹⁴. These reports suggest that although uncommon, cerebrovascular events related to left upper extremity arterial catheterization are a real risk and need to be considered when undertaking procedures utilizing this access approach. Even if a heparin-coated catheter is used, fibrin and clots can embolize to the left vertebral artery, resulting in brain infarction¹⁰. In this study, there were no serious complications such as brain infarction. The main reason we chose the femoral route over the subclavian approach was to prevent brain infarction, especially in the left vertebral artery territory. Furthermore, using transsubclavian access, blood flow redistribution had to be performed via the femoral artery, while the infusion

catheter was placed via the left subclavian artery. Transfemoral access, however, allows blood flow redistribution and infusion catheter placement to be performed in the same session.

According to recent reports on complications of PCS implanted using the transsubclavian route (Table 3), arterial injury occurred in 4.5%–18.0%^{6,11,12}, pocket trouble in 2.6%–10.0%^{5,7,11}, port-catheter obstruction in 0%–25.0%^{5,6,15,16} and significant catheter dislodgement from the target artery in 0.9%–14.5%^{6,11,12}. The technical success rate was reported to be 92.0%–100%^{5,6,11,12}. Our data show hepatic arterial injury in 7.8%, pocket trouble in 4.9%, port-catheter obstruction in 3.9% and catheter dislodgement from the target artery in 2.9%. The technical success rate was 94.7%. Our complication rates using the transfemoral access were favorable compared with some reports of transsubclavian access. Furthermore our outcome is in no way inferior to other reports of transfemoral access (Table 3).

Thrombotic complication such as occlusion of the hepatic artery is commonly associated with both transfemoral and transsubclavian access. The material and thickness of indwelling catheters^{17,18} and the relation between the size of the catheter and the lumen of the target vessel⁸ are important in this context. We experienced two cases of immediate

common hepatic artery occlusion after placing the infusion catheter before this study. The common hepatic artery in these two cases was narrow compared with other cases. Since it is suggested that a narrow common hepatic artery is easily occluded, the infusion catheter should be placed in the splenic artery with a side hole at the origin of the common hepatic artery. When a 5 Fr infusion catheter could not be placed due to narrowing of the common hepatic artery, Herrmann *et al.*⁸) and Kuroiwa *et al.*⁹) tried to use a 3 Fr microcatheter system. As reported by Neiderhünver *et al.*¹⁹) and Strum *et al.*²⁰) catheters with small diameters have higher occlusion rates. Owing to the higher resistance of small catheters, drug infusion may also be difficult²⁰). We have not used the infusion microcatheter, but it should be investigated in the future as an option in cases with a narrow common hepatic artery. In addition, the toxic effects of the chemotherapeutic agents have been blamed for some form of damage to the vessel wall of the hepatic artery^{17,21–24}). It was suggested that our two cases of ulceration of the vessel wall were induced by the toxic effect of anticancer drugs. Grosso *et al.*⁶) and Huk *et al.*²⁵) reported that administration of anticoagulation therapy would reduce arterial thrombosis and achieve long-term patency of the implanted arterial device. Other

Table 3 Review of the complications of continuous intraarterial chemotherapy using implanted port-catheter system via the left subclavian/brachial access (the upper section) and via the femoral access including our data (the lower section).

Reference	No. of Patients	Arterial injury	port-catheter obstruction	pocket infection	catheter dislocation	brain infarction	overall complications
Grosso ⁶)	200	6.0%	0	0	14.5%	0	21.5%
Strecker ⁷)	44	9.1%	11.3%	4.5%	9.1%	0	25.0%
Minoyama ¹¹)	31	13.2%	5.3%	2.6%	0.9%	2.6%	22.0%
Habbe ¹²)	61	18.0%	0	0	9.0%	1.8%	28.5%
Oi ¹⁵)	31	12.9%	0	0	12.9%	0	35.4%
Wacker ¹⁷)	33	9.0%	15.0%	0	19.0%	0	60.6%
Herrman ⁸)	32	0	6.0%	0	6.0%	0	12.0%
Kuroiwa ⁹)	88	12.5%	11.0%	3.4%	10.0%	0	27.0%
Heianna (this study)	102	7.8%	3.9%	3.9%	2.9%	0	17.6%

authors^{7-9,19)}, however, do not consider systemic or other types of anticoagulation therapy necessary because of the potential side effects of anticoagulation therapy and the increased need for blood parameter analysis. In our patients group, we experienced a low rate of arterial thrombosis (5.3%) without use of any anticoagulation therapy.

Infection is another complication in a permanently implanted PCS that often makes removal of the device necessary^{7,25,26)}. Infection and sepsis during chemotherapy can be caused by use of inappropriate hygienic measures. Strecker *et al.*⁷⁾ noticed that after an infected PCS was removed and replaced with a new one, however, infection recurred in some patients. We believe the infected PCS should be removed immediately because it could result in pseudoaneurysm⁶⁾ of the femoral artery at the site of catheter insertion and the system should not be replaced.

Obstruction of the PCS is a serious complication of intraarterial infusion chemotherapy. The likely cause of obstruction over the short term appears to be insufficient periodic heparinization of the port system. Frequent heparinization of the port system (at least every 10 days to 14 days) is important to maintain catheter patency. Lytic therapy with tissue plasminogen activator, urokinase, or streptokinase has been reported to be useful in cases of catheter occlusion^{7,17,20)}, but this method is not always successful²⁶⁾.

In order to prevent catheter dislodgement, catheter tips are fixed to the vessel wall with metallic coils in some institutions²⁷⁾. However, once such a method is employed, it is difficult to remove the PCS in case of infection or obstruction. Therefore we usually place the infusion catheters without fixation. According to Strecker *et al.*⁷⁾ and Kuroiwa *et al.*⁹⁾, catheter-related dislocation could be due to the catheter material, which should not be too soft and flexible. However, we believe catheter dislodgement was probably due to too much tension on the indwelling catheter rather than to the material. Therefore, it is important to leave some slack in the infusion catheter at the abdominal aorta.

To prevent chemotoxicity, blood flow redistribution by transcatheter arterial embolization (TAE) of the right gastric artery or pancreatic branches is necessary. Incomplete TAE may result in recanalization and drug-induced side effects. In our case, recanalization of the right gastric artery may have resulted in drug-induced gastric ulcer.

Placement of the PCS on the anterior surface of the thigh below the groin seems to be well accepted, even in very active patients. Its superficial placement allows easy palpation and puncture, even in obese patients, and it provides little risk for dislocation or disconnection of the port needle from the port during chemotherapy.

In conclusion, our data suggested that it was feasible and safe to place the PCS via the femoral artery, and that implantation of a PCS using the femoral approach may be as effective as implantation via the subclavian/brachial approach.

Acknowledgment

The authors gratefully acknowledge the secretarial assistance of Ms. Koko Igarashi.

References

- 1) Begos, D.G. and Ballantyne, G.H. (1994) Regional chemotherapy for colorectal liver metastases: thirty years without patient benefit. *J. Surg. Oncol.*, **56**, 139-144.
- 2) Kemeny, N., Seiter, K., Conti, J.A., Cohen, A., Bertino, J.R., Sigurdson, E.R., Bo, C.D., Mazumdar, M. and Budd, A.J. (1994) Hepatic arterial floxuridine and leucovorin for unresectable liver metastases from colorectal carcinoma. *Cancer*, **73**, 1134-1142.
- 3) Ravikumar, T.S., Pizzoma, G., Bodden, W., Marsh, J., Strair, R., Pollack, J., He, R., Hanna, J. and D'Andrea, E. (1994) Percutaneous hepatic vein isolation and high-dose hepatic arterial infusion chemotherapy for unresectable liver tumors. *J. Clin. Oncol.*, **12**, 2723-2736.
- 4) Arai, Y. (1988) Study of catheter placement

- in the hepatic artery via the left subclavian artery for hepatic infusion therapy. *J. Nagoya City Univ. Med. School*, **39**, 453-464.
- 5) Hayashi, N., Sakai, T., Kitagawa, M., Kimoto, T. and Ishii, Y. (1998) Percutaneous long-term arterial access with implantable ports: Direct subclavian approach with US. *Eur. J. Radiol.*, **26**, 304-308.
 - 6) Grosso, M., Zanon, C., Mancini, A., Garruso, M., Gazzera, C., Anselmetti, G.C., Veglia, S. and Gandini, G. (2000) Percutaneous implantation of a catheter with subcutaneous reservoir for intraarterial regional chemotherapy: Technique and preliminary results. *Cardiovasc. Intervent. Radiol.*, **23**, 202-210.
 - 7) Strecker, E.P., Boos, I.B., Ostheim, D.W., Hever, R. and Vetter, S.C. (1997) Percutaneously implantable catheter-port system: Preliminary technical results. *Radiology*, **202**, 574-577.
 - 8) Herrmann, K.A., Waggershauer, T., Sittek, H. and Reiser, M.F. (2000) Liver intraarterial chemotherapy: Use of the femoral artery for percutaneous implantation of catheter-port systems. *Radiology*, **215**, 294-299.
 - 9) Kuroiwa, T., Honda, H., Yoshimitsu, K., Irie, H., Aibe, H., Tajima, T., Shinozaki, K. and Masuda, K. (2001) Complications encountered with a transfemorally placed port-catheter system for hepatic artery chemotherapy infusion. *Cardiovasc. Intervent. Radiol.* **24**, 90-93.
 - 10) Ozawa, Z., Morita, S., Hata, Y. and Horimi, T. (1995) Two cases of cerebral and/or cerebellar infarction after reservoir implantation through the left subclavian arterial route. *Interv. Radiol.*, **10**, 449-452.
 - 11) Minoyama, A., Yoshikawa, M., Ebara, M., Saisho, H., Sugiura, N. and Ohto, M. (1995) Study of repeated arterial infusion chemotherapy with a subcutaneously implanted reservoir for advanced hepatocellular carcinoma. *J. Gastroenterol.*, **30**, 356-366.
 - 12) Habbe, T.G., McCowan, T.C., Goertzen, T., Leveen, R.F., Culp, W.C. and Tempero, M.A. (1998) Complications and technical limitations hepatic arterial infusion catheter placement for chemotherapy. *J. Vasc. Interv. Radiol.*, **9**, 233-239.
 - 13) Toyoda, H., Nakano, S., Kumada, T., Takeda, I., Sugiyama, K., Osada, T., Kiriya, S., Suga, T. and Takahashi, M (1995) The efficacy of continuous local arterial infusion of 5-Fluorouracil and cisplatin through an implanted reservoir for severe advanced hepatocellular carcinoma. *Oncology*, **52**, 295-299.
 - 14) Head, R.M. and Robboy, S.J. (1972) Embolic stroke from mural thrombi, a fatal complication of axillary artery catheterization. *Radiology*, **102**, 307.
 - 15) Oi, H., Kishimoto, H. Matsushita, M., Hori, M. and Nakamura, H. (1996) Percutaneous implantation of hepatic artery infusion reservoir by sonographically guided left subclavian artery puncture. *Am. J. Roentgenol.*, **166**, 821-822.
 - 16) Arai, Y., Inaba, Y. Takeuchi, Y. and Ariyoshi, Y. (1997) Intermittent hepatic arterial infusion of high-dose 5 FU on a weekly schedule for liver metastases from colorectal cancer. *Cancer. Chemother. Pharmacol.*, **40**, 526-530.
 - 17) Wacker, F.K., Boese-Landgraf, J., Wagner, A., Albrecht, D., Wolf, K.J. and Fobbe, I. (1997) Minimally invasive catheter implantation for regional chemotherapy of the liver: a new percutaneous transsubclavian approach. *Cardiovasc. Intervent. Radiol.*, **20**, 128-132.
 - 18) Balestreri, L., De Cicco, M., Matovic, M., Coran, F. and Morassut, S. (1995) Central venous catheter-related thrombosis in clinically asymptomatic oncologic patients: a phlebographic study. *Eur. J. Radiol.*, **20**, 108-111.
 - 19) Niederhuber, J.E., Ensminger, W., Gyves, J.W., Liepman, M., Doan, K. and Cozzi, E. (1982) Totally implanted venous and arterial access system to replace external catheters in cancer treatment. *Surgery*, **92**, 706-712.
 - 20) Strum, S., McDermed, J., Korn, A. and Joseph, C. (1986) Improved methods for venous access: the port-A-Cath-a totally implanted catheter system. *J. Clin. Oncol.*, **4**, 596-603.
 - 21) Forsberg, L., Hafstrom, L., Lunderquist, A. and Sundqvist, K. (1978) Arterial changes during

- treatment with intra-arterial infusion of 5-fluorouracil. *Radiology*, 126, 49-52.
- 22) Charnsangavej, C., Kirk, I.R., Dubrow, R.A., Chuang, V.P., Curley, S.A., Roh, M.S., Varma, D.G. and Patt, Y.Z. (1993) Arterial complications from long-term hepatic artery chemoinfusion catheters: evaluation with CT. *Am. J. Roentgenol.*, **160**, 859-864.
- 23) Bledin, A.G., Kim, E.E., Chuang, V.P., Wallace, S. and Haynie, T.P. (1984) Changes of arterial blood flow patterns during infusion chemotherapy, as monitored by intra-arterially injected technetium 99m macroaggregated albumin. *Br. J. Radiol.*, **57**, 197-203.
- 24) Roth, J., Wallner, B. and Safi, F. (1989) Arterial perfusion abnormalities of the liver after hepatic arterial infusion chemotherapy and their correlation with changes in the metastases: evaluation with CT and angiography. *Am. J. Roentgenol.*, **153**, 751-754.
- 25) Huk, I., Entscheff, P., Prager, M., Schulz, F., Polterauer, P. and Funovics J. (1990) Patency rate of implantable devices during long-term intraarterial chemotherapy. *Angiology*, **41**, 936-941.
- 26) Jakob, A.R., Kuhl, M., Jauch, K.W., Schalhorn, A. and Wilmanns, W. (1996) Complications using implantable port-systems for regional chemotherapy of liver metastases. *Reg. Cancer. Treat.*, **9**, 33-36.
- 27) Takayasu, Y., Inoue, J., Yamano, T. and Nakano, N. (1998) Intra-arterial infusion chemotherapy for metastatic liver tumors: Indications and limitations. *Interv. Radiol.*, **13**, 304-307.